WILDERNESS MEDICINE "PEARLS"

Gary Johnson MD
University of Nevada Reno
Family Medicine Residency Program

NAFP WINTER CME MEETING

DALE CARNEGIE® TRAINING Copyright, 1996 © Dale Carnegie & Associates, Inc.

PEARL # 1

•IMPROVISATION WORKS BEST WHEN PREPARED FOR WELL IN ADVANCE

SNAKE BITE

CONSIDER:

- Is the snake venomous or non venomous
- Has envenomation occurred?
- Is the victim young, pregnant, ill or far from definitive care?
- Does any treatment need to occur prior to transport?

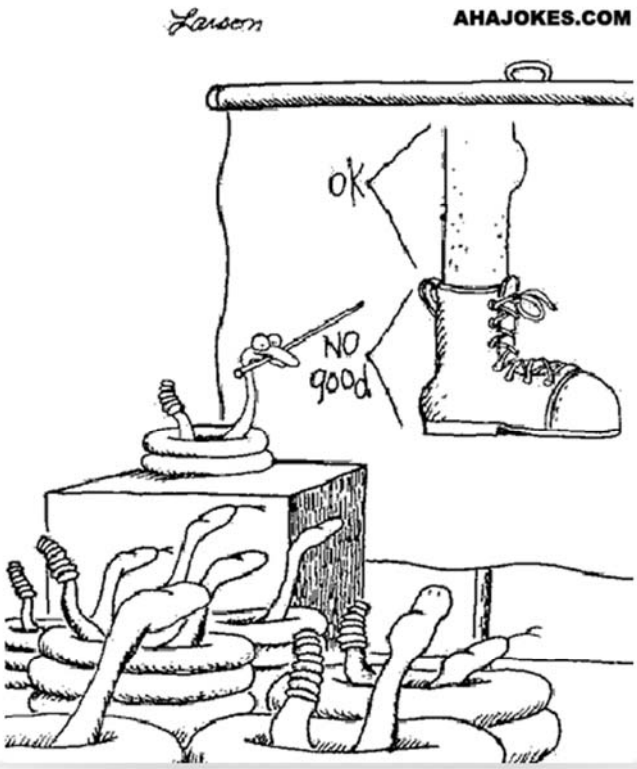

FEATURES OF VENOMOUS SNAKES (PIT VIPERS.)

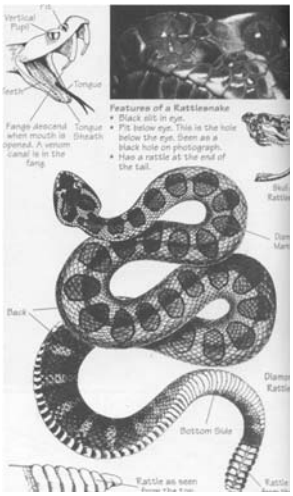

- **IDENTIFICATION**
- Triangular shaped head.
- Heat sensing pits.
- Rattles
- Fangs.

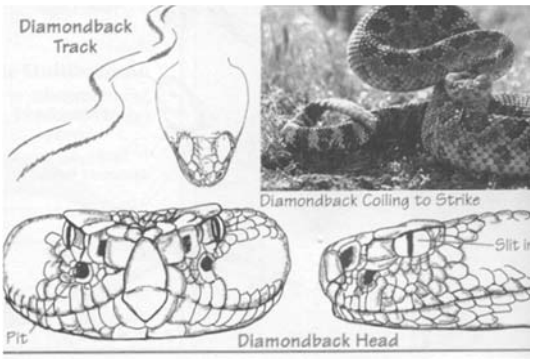

"

ENVENOMATION

- Venom is a hemotoxin (except Mojave rattle snake)
- Injection of venom may not occur:
- is it a 'dry bite'?
- Signs/symptoms: erythema,
- pain, edema, systemic
- Symptoms usually obvious
- within 15 minutes

TABLE 38-3. Signs and Symptoms of Rattlesnake Bites

SIGN OR SYMPTOM	FREQUENCY*
Fang marks	100/100
Swelling and edema	74/100
Pain	65/100
Ecchymosis	51/100
Vesiculations	40/100
Change in pulse rate	60/100
Weakness	72/100
Sweating, chills	64/100
Numbness or tingling of tongue and mouth, scalp, or feet	63/100
Faintness or dizziness	57/100
Nausea, vomiting, or both	48/100
Blood pressure changes	46/100
Change in body temperature	31/100
Swelling regional lymph nodes	40/100
Fasciculations	41/100
Increased blood clotting time	39/100
Sphering of red blood cells	18/100
Tingling or numbness of affected part	42/100
Necrosis	27/100
Respiratory rate changes	40/100
Decreased hemoglobin	37/100
Abnormal electrocardiogram	26/100
Cyanosis	16/100
Hematemesis, hematuria, or melena	15/100
Glycosuria	20/100
Proteinuria	16/100
Unconsciousness	12/100
Thirst	34/100
Increased salivation	20/100
Swollen eyelids	2/100
Retinal hemorrhage	2/100
Blurring of vision	12/100
Convulsions	1/100
Muscle contractions	6/100
Increased blood platelets	16/100
Decreased blood platelets	42/100

Modified from Russell FE: *Snake venom poisoning.* New York, 1983, Scholium International

*Number of times the symptom or sign was observed per total number of patients.

SIGNS AND SX'S

Figure 38-24 Mottled rock rattlesnake *(Crotalus lepidus lepidus)* bite in a young man at 24 hours. Note the exudation of red cells into the soft tissues remote from the bite site. The man was bitten on his left thumb. *(Robert Norris, MD.)*

Figure 38-25 Hemorrhagic bleb at the site of a western diamondback rattlesnake *(Crotalus atrox)* bite at 24 hours. *(Robert Norris, MD.)*

TREATMENT

- Hospitalize: observation vs acute/ICU stay

  Non-envenomation: monitor 8 h
- Monitor for shock, compartment syndrome, local tissue necrosis, coagulopathy
- Antivenin (Cro-fab)
- ?Broad spectrum antibiotics: prophylaxis no longer recommended.
- Consider Tetanus toxoid.

Figure 38-27 Rarely indicated fasciotomy in a victim of severe rattlesnake bite *(Crotalus viridis helleri)*. Compartment pressures were greater than 60 mm Hg despite aggressive antivenom therapy. *(Robert*

CONTROVERSIES

- Tourniquets (venous, lymphatic, arterial)
- Freezing
- Fasciotomy
- Snake bite kits (cut and suck…)
- Electric shock

- With exception of lymphatic tourniquet and suction only devices : none of the above recommended.

PEARL #2

- YOUR MOST IMPORTANT SURVIVAL TOOLS ARE YOUR PHONE AND YOUR CAR KEYS

IMBEDDED FISH HOOKS

- If barb not engaged, may just retract.
    - Advance hook through skin until barb exposed
- Clip off end of hook with barb,

  retract

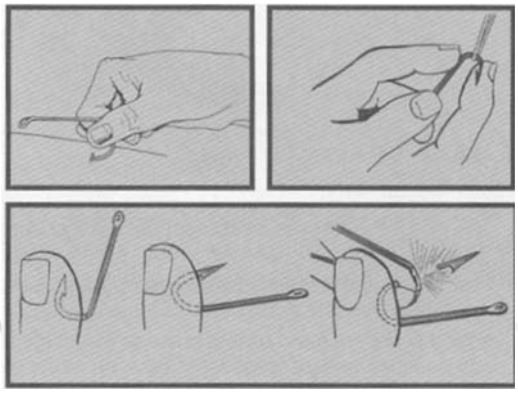

STRING TECHNIQUE

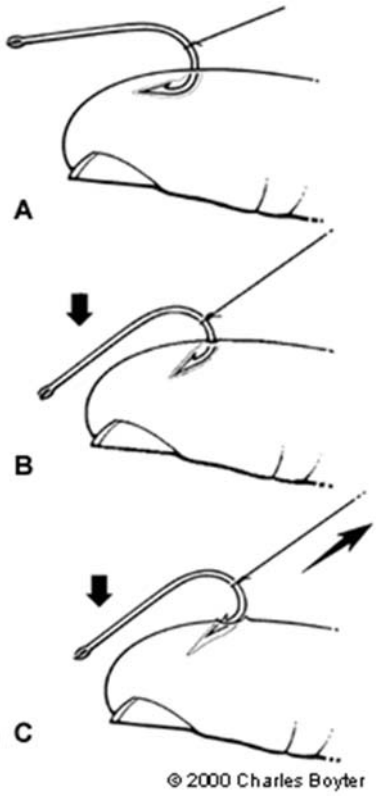

NECROTIZING LESIONS

BROWN RECLUSE (LOXSOCELES)

Nevada is NOT part of natural range of brown recluse spiders.
Bites rare even when endemic: (reclusive!)

- Small, brown spider with “violin” on thorax
- Venom causes tissue necrosis
- Wide prophylactic excision no
- longer recommended
- If documented: consider dapsone,
- but no systemic therapy
- currently accepted



A COMMENT ON LOXSOCELES:

- Brown recluse spider bites commonly blamed for localized areas of skin necrosis. Much more common: MRSA, pyoderma.
- Undistinguished appearing spider: bites over-diagnosed in this area
- These spiders actually rare outside of south-central U.S. (Tennessee to Missouri)

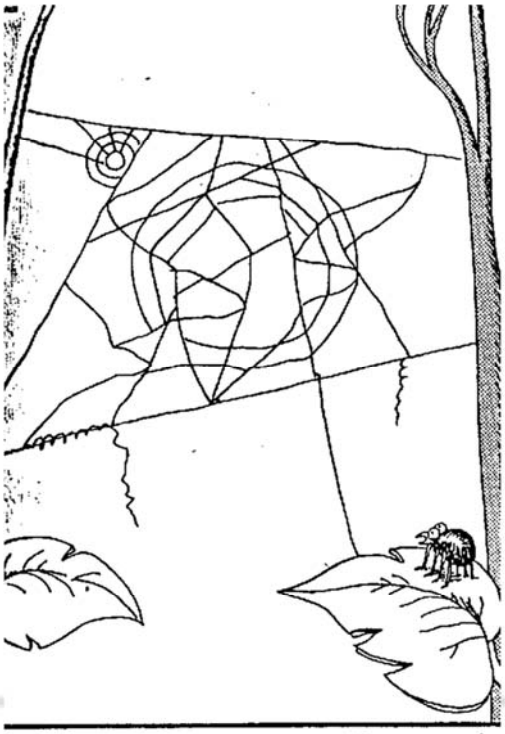

"Whoa! . . . That CAN'T be right!"

"REAL MEN NEVER FILTER"

PEARL #3

- JUST BECAUSE YOU **COULD** DO AN APPENDECTOMY WHILE CAMPING DOESN'T MEAN YOU **SHOULD**

SUNBURN

- Local pain, erythema, fever, malaise
- Topical vs systemic steroids
- Anti-inflammatory meds
- Watch for phototoxic reactions
- Snowblindness

SUBUNGUAL SPLINTERS

A PAUSE FOR REFRESHMENT…

DUTCH OVEN AND CAMPFIRE COOKING…..

- Or: WHY WE CAMP!

PEARL #4

- **FIRST AID KITS ARE MUCH MORE USEFUL WHEN NOT LEFT SITTING ON A SHELF IN THE GARAGE**

Sea Urchins

- Remove spines: granulomatous reaction, secondary infection
- Tattooing may confuse the picture



A SCENARIO:

- YOU'VE BROKEN YOUR SUNGLASSES THE FIRST DAY OF A FOUR DAY WINTER BACK PACKING TRIP. YOU CAN'T SEE DISTANCES VERY WELL AND YOU ARE WORRIED ABOUT SNOW BLINDNESS.

- ARE THERE ANY OPTIONS?

DUCT TAPE SUNGLASSES!

SCORPION STRIKE

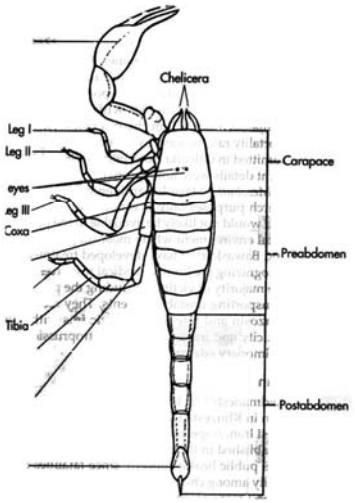

Figure 35-2 Anatomy of a scorpion. *(Redrawn from Keegan HL: Scorpions of medical importance, Oxford, Miss, 1980, University Press of Mississippi).*

STINGING APPARATUS

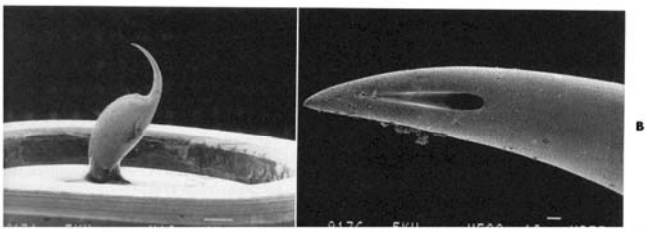

SCORPIONS

Continental U.S. generally benign:
(exception is the
Arizona Bark Scorpion)

- Erythema, nausea
- Treatment: supportive

- In Mexico:
  1000 deaths a year still occur from scorpion stings!

PEARL #5

- IF YOU DON'T KNOW WHERE YOU ARE GOING AND WHEN YOU'LL BE BACK: DON'T GO.

Lion/Tiger Fish

- Contact through salt water tanks, tropical diving or snorkeling.
- Severe local reactions
- Treat by immersion

  in hot water

VESICULATION 48 H POST LIONFISH STING

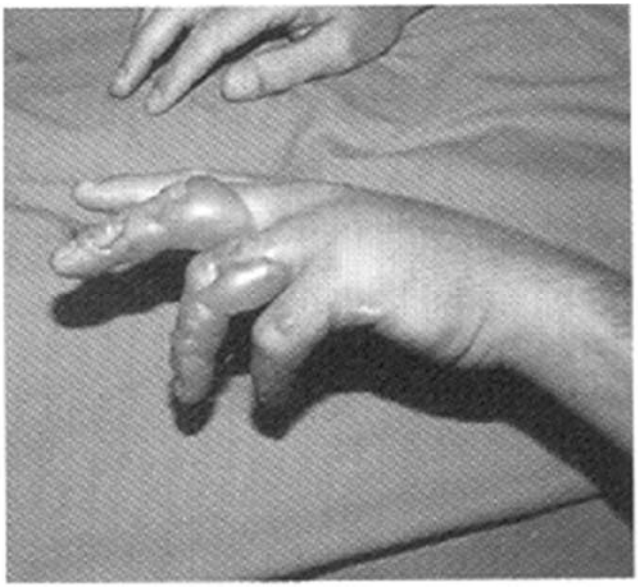

PEARL #6

- IF YOU HAVE TO RUN A CODE IN THE WILDERNESS, YOU'VE ALREADY LOST THE BATTLE

MYSTERY RASH...

LINEAR, PRURITIC VESICLES…..

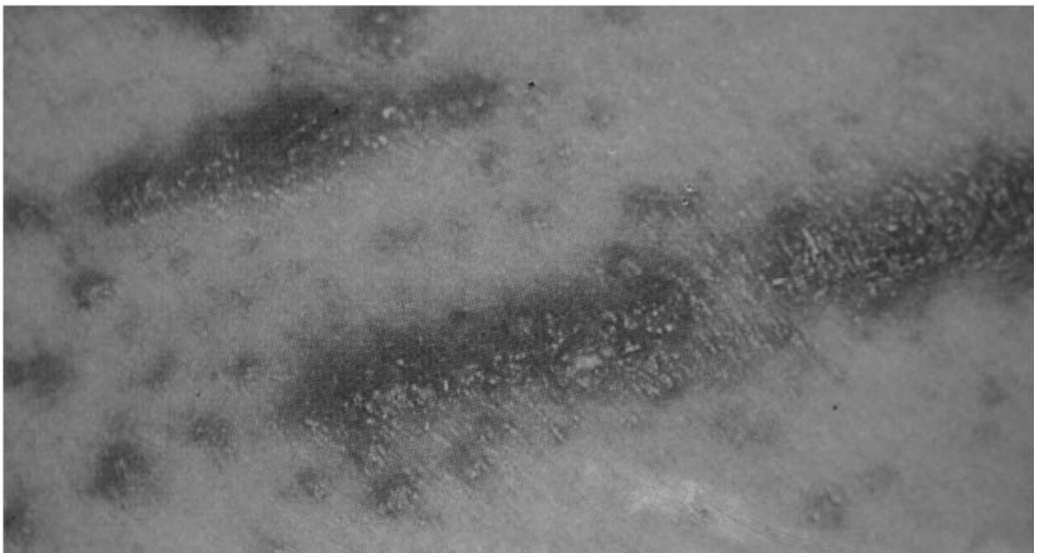

POISON OAK/IVY

- Shiny, trifoliate leaves: “leaves of three, let it be.”
- Erythematous, vesicular, pruritic, often linear rash.
- Antigen spread by smoke, clothes.
- Treatment: topical or systemic steroids.
- Prophylactic barrier methods.

POISON OAK DERMATITIS

Or: be careful what you wipe with!

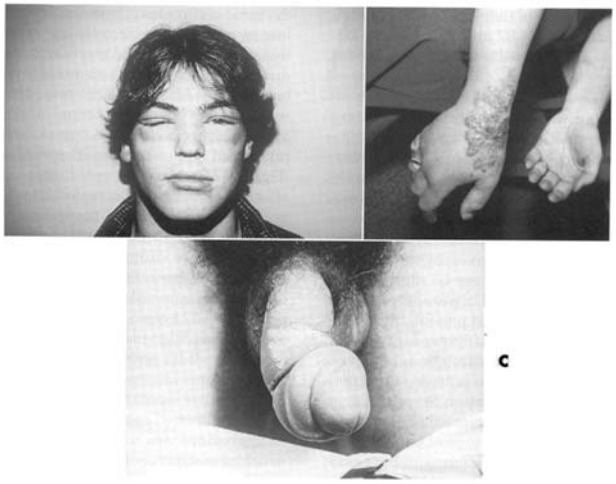

SUBUNGUAL HEMATOMA

- Pain, pressure due to expanding hematoma in closed space
- Treat within 12 hours or hematoma becomes organized
- Hot paper clip, hand drill, needle or hyfercating device
- Immobilize hand!

HOT PAPER CLIP TECHNIQUE

WHY WE CAMP (PART II)

PEARL # 7

- IT'S WORTH KNOWING SOME WILDERNESS MEDICINE EVEN IF YOU'LL NEVER VENTURE FURTHER THAN THE NEAREST HILTON

- Be prepared for the unexpected.

THE END

- Stick around for the workshop….